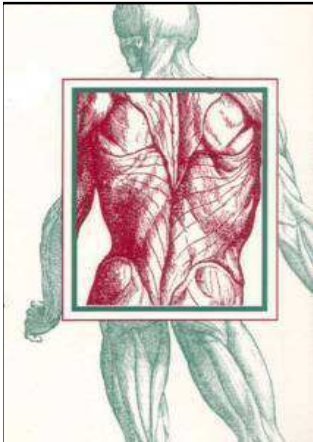


Kreuzschmerzen



Einführung

ISG

Facetten

Discus

Take Home

Radiofrequenztherapie an der Wirbelsäule



P. Machacek, C.Thalhamer

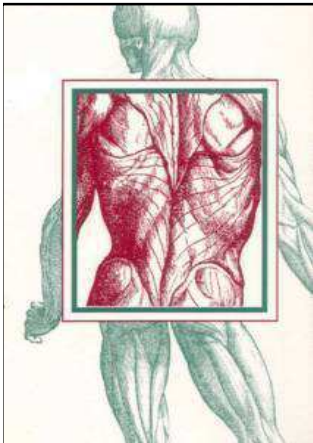
Abteilung für konservative Orthopädie, Wien Speising

Kreuzschmerzen



Kreuzschmerz (Low back Pain)

Definition: Schmerzen im Bereich zwischen den **12. Rippen** und den unteren **Glutealfalten**



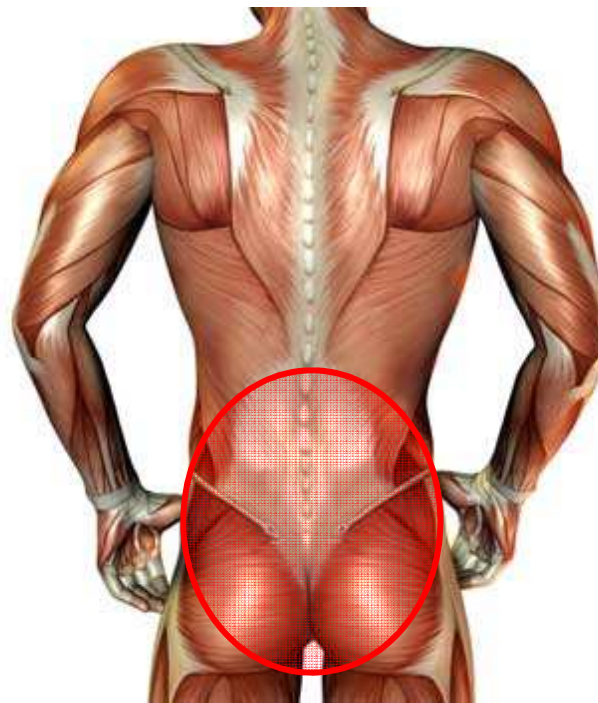
Einführung

ISG

Facetten

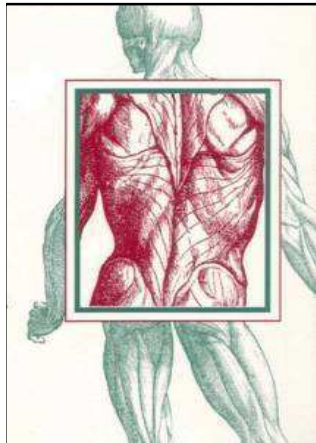
Discus

Take Home



The Back Pain Revolution (1998)
[Gordon Waddell](#)

Kreuzschmerzen



Kreuzschmerz (Low back Pain)

spezifisch:



unspezifisch



- Neoplasmen
- Entzündungen
- Infektionen
- Verletzungen
- Metabolische Erkrankungen
- Psychische Erkrankungen
- Nervenwurzelirritationen
- Cauda equina Syndrom
- Degenerative Erkrankungen



80 - 85 %

Einführung

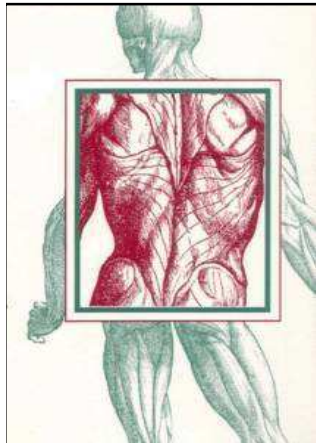
ISG

Facetten

Discus

Take Home

Kreuzschmerzen



Einführung

ISG

Facetten

Discus

Take Home

Kreuzschmerz (Low back Pain)

unspezifisch

[Br Med J.](#) 1966 Jul 9;2(5505):82-4.
Acute back syndrome-a study from general practice.
[Dillane JB](#), [Fry J](#), [Kalton G](#).


[Scand J Work Environ Health.](#) 1982 Jun;8(2):134-6.
Classification of low-back pain.
[Nachemson AL](#), [Andersson GB](#)

[Eur Spine J.](#) 2007 Oct;16(10):1539-50.
Systematic review of tests to identify the disc, SIJ or facet joint as the source of low back pain.
[Hancock MJ](#), [Maher CG](#), [Latimer J](#), [Spindler MF](#), [McAuley JH](#), [Laslett M](#), [Bogduk N](#)



80 - 85 %

Kreuzschmerzen



Einführung

ISG

Facetten

Discus

Take Home

Kreuzschmerz (Low back Pain)



unspezifisch



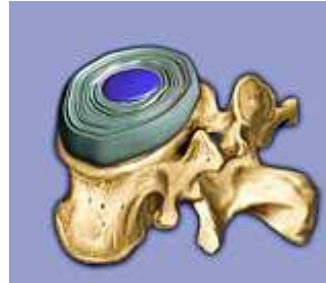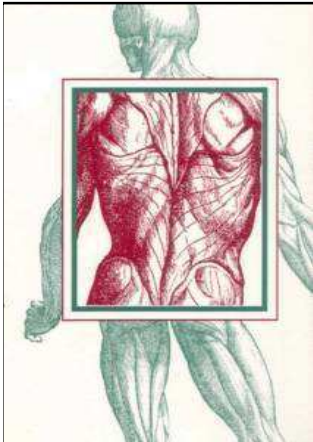
Pain Med 2011 Feb;12(2):224-33.

What is the source of chronic low back pain and does age play a role?

DePalma MJ, Ketchum JM, Saullo T.

10 % !

Kreuzschmerzen



- Einführung**
- ISG
- Facetten
- Discus
- Take Home


Source	Study	Age ⁺ (years)	Prevalence (%)	95% CI (%)	Prevalence (%)	95% CI (%)
IDD	Schwarzer (a)	36.7	39	(29, 49)	77.2	(67.0, 87.3)
	Manichikanti (b)	~47	26	(18, 34)	55.0	(45.4, 64.5)
FJP	Schwarzer (c)	38.4	15	(10, 20)	16.2	(8.1, 24.3)
	Schwarzer (d)	59	32	(20, 44)	40.7	(31.7, 49.8)
	Manichikanti (e)	~47	27	(22, 33)	27.5	(19.1, 36.0)
SIJP	Schwarzer (f)	32.8	30	(16, 44)	5.3	(0.7, 9.8)
	Schwarzer (f)	32.8	13	(6, 44)	5.3	(0.7, 9.8)
	Maigne (g)	45.3	18.5	—	12.9	(6.4, 19.5)

[Pain Med.](#) 2011 Feb;12(2):224-33.

What is the source of chronic low back pain and does age play a role?

[DePalma MJ](#), [Ketchum JM](#), [Saullo T](#).

Kreuzschmerzen



Iliosacralgelenk

[Man Ther.](#) 2000 Feb;5(1):30-6.

Clinical tests of the sacroiliac joint. A systematic methodological review. Part 1: Reliability.

[van der Wurff P](#), [Hagmeijer RH](#), [Meyne W](#).

[Man Ther.](#) 2000 May;5(2):89-96.

Clinical tests of the sacroiliac joint.

[van der Wurff P](#), [Meyne W](#), [Hagmeijer RH](#).

[Man Ther.](#) 2007 Feb;12(1):72-9. Epub 2006 Jul 12.

The reliability of selected motion- and pain provocation tests for the sacroiliac joint.

[Robinson HS](#), [Brox JI](#), [Robinson R](#), [Bjelland E](#), [Solem S](#), [Telje T](#)

[Aust J Physiother.](#) 2003;49(2):89-97.

Diagnosing painful sacroiliac joints: A validity study of a McKenzie evaluation and sacroiliac provocation tests.

[Laslett M](#), [Young SB](#), [Aprill CN](#), [McDonald B](#).

[Aust J Physiother.](#) 2006;52(3):229.

Pain provocation tests for diagnosis of sacroiliac joint pain.

[Laslett M](#).

Einführung

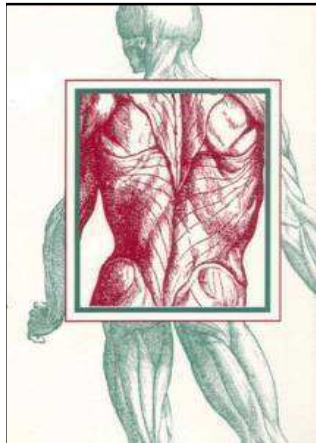
ISG

Facetten

Discus

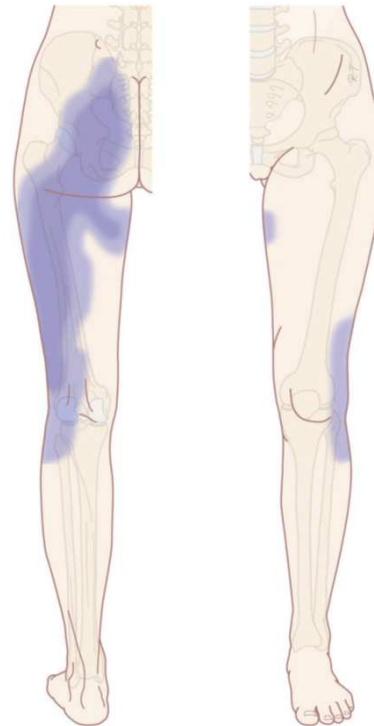Take Home

Kreuzschmerzen



Iliosacralgelenk

Schmerzprojektion bei ISG Affektion :



Vanelderen et. al,
Pain Pract 2010

Einführung

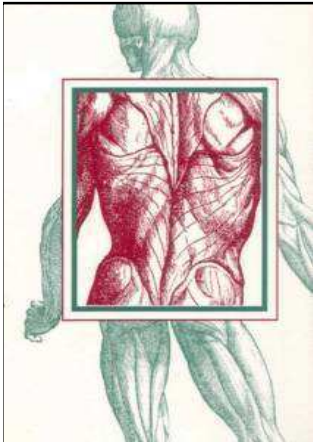
ISG

Facetten

Discus

Take Home

Kreuzschmerzen



Radiofrequenztherapie (RF) des Iliosacralgelenkes (ISG)

Voraussetzung: positive Testung mittels
intraartikulärer Probeinfiltration

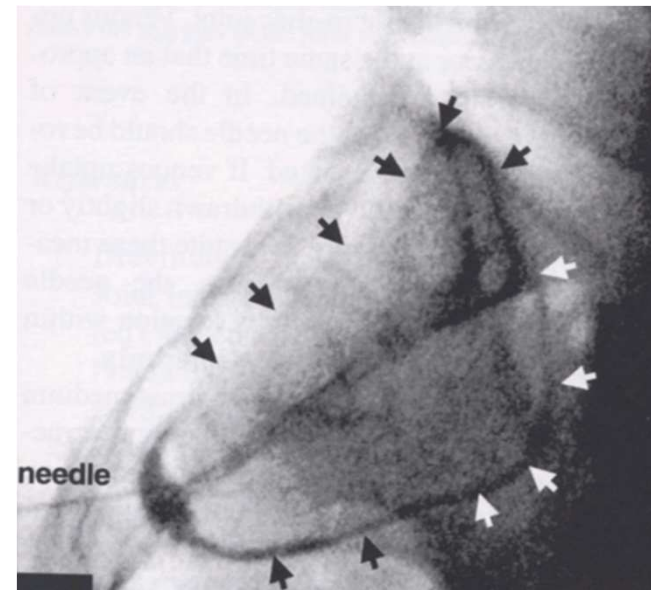
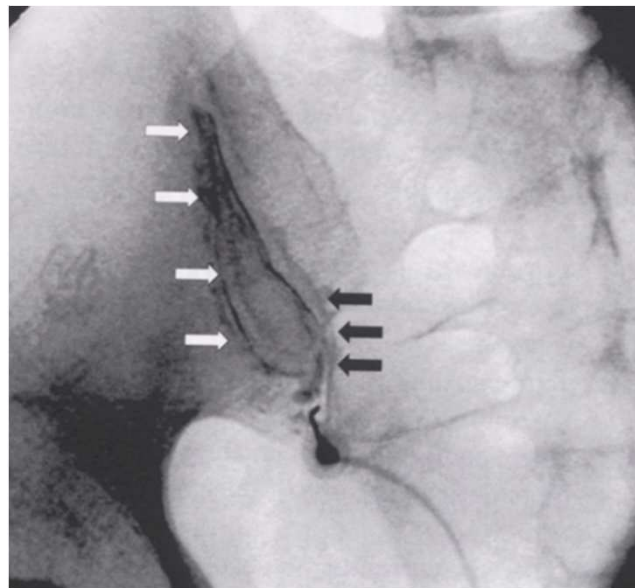
Einführung

ISG


Facetten

Discus

Take Home

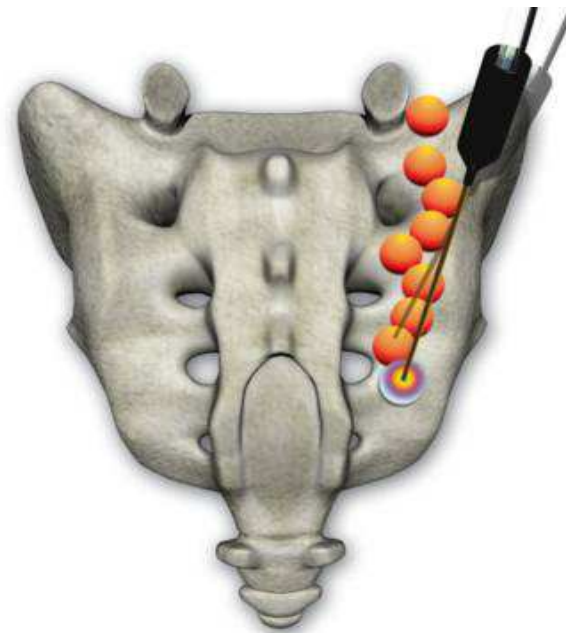


Kreuzschmerzen



Radiofrequenztherapie (RF) des Iliosacralgelenkes (ISG)

Technik : mit gekühlter Radiofrequenzsonde



Einführung

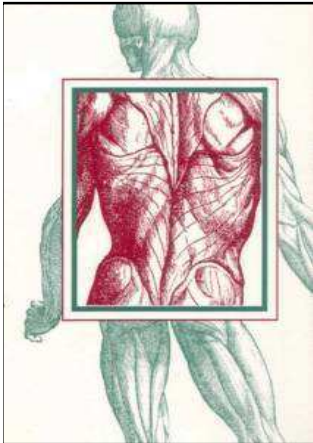
ISG

Facetten

Discus

Take Home

Kreuzschmerzen



Einführung

ISG

Facetten

Discus

Take Home

Radiofrequenztherapie (RF) des Iliosacralgelenkes (ISG)

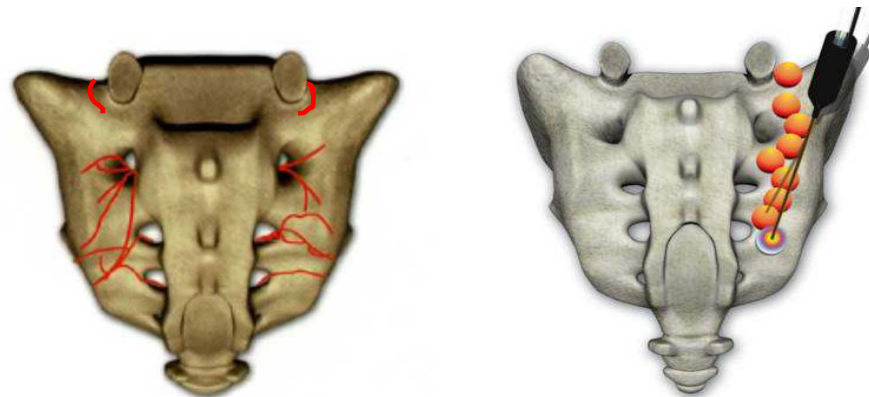



Table 1. Summary of Evidence Scores and Implications for Recommendation

Score	Description	Implication
1 A+	Effectiveness demonstrated in various RCTs of good quality. The benefits clearly outweigh risk and burdens	Positive recommendation
1 B+	One RCT or more RCTs with methodologic weaknesses, demonstrate effectiveness. The benefits clearly outweigh risk and burdens	
2 B+	One or more RCTs with methodologic weaknesses, demonstrate effectiveness. Benefits closely balanced with risk and burdens	Considered, preferably study-related
2 B±	Multiple RCTs, with methodologic weaknesses, yield contradictory results better or worse than the control treatment. Benefits closely balanced with risk and burdens, or uncertainty in the estimates of benefits, risk and burdens.	
2 C+	Effectiveness only demonstrated in observational studies. Given that there is no conclusive evidence of the effect, benefits closely balanced with risk and burdens	
0	There is no literature or there are case reports available, but these are insufficient to suggest effectiveness and/or safety. These treatments should only be applied in relation to studies.	Only study-related
2 C-	Observational studies indicate no or too short-lived effectiveness. Given that there is no positive clinical effect, risk and burdens outweigh the benefit	Negative recommendation
2 B-	One or more RCTs with methodologic weaknesses, or large observational studies that do not indicate any superiority to the control treatment. Given that there is no positive clinical effect, risk and burdens outweigh the benefit	
2 A-	RCT of a good quality which does not exhibit any clinical effect. Given that there is no positive clinical effect, risk and burdens outweigh the benefit	

RCT, randomized controlled trial.

Vanelderen et al, Pain Pract 2010
Evidenzgrad für ISG-Denervierung mit gekühlter RF

Kreuzschmerzen



Facettensyndrom

Klinik

In 1 Dimension in der Regel NICHT auslösbar

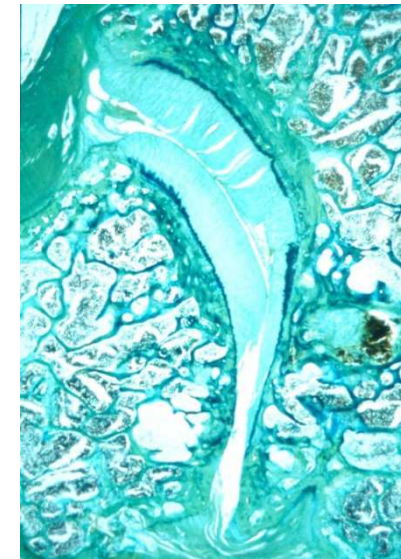
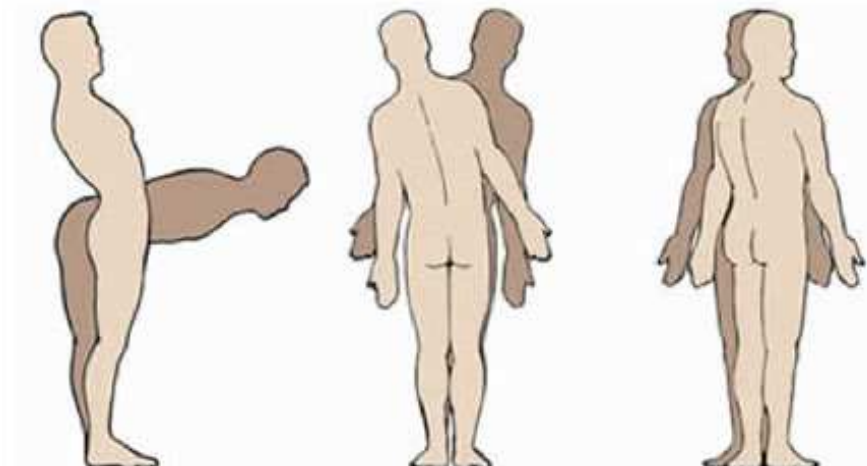
Einführung

ISG


Facetten

Discus

Take Home



Kreuzschmerzen



Einführung

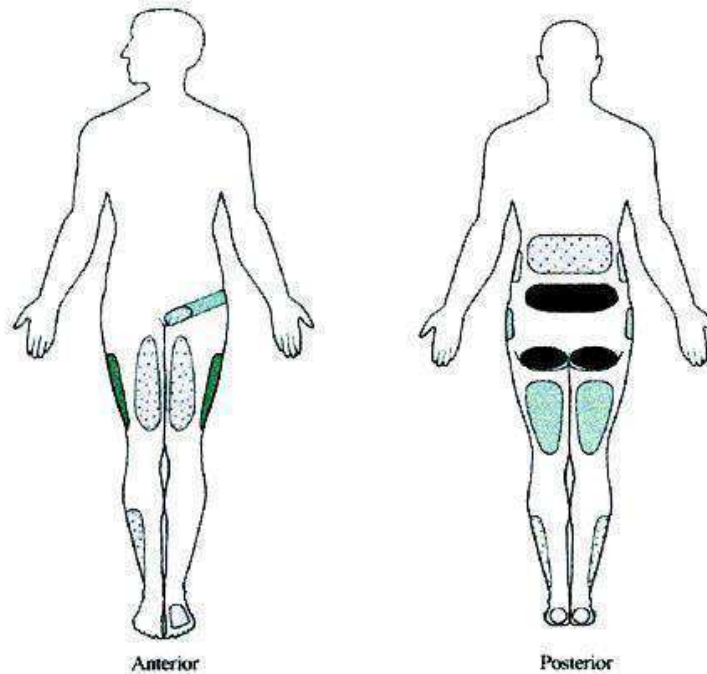
ISG

Facetten

Discus


Take Home

Facettensyndrom



Zusammenfassung von 17 Arbeiten über
Schmerzausstrahlung bei lumbal facet joint pain
[Cohen & Raja. Anesthesiology 2007; 106: 591-614](#)

Kreuzschmerzen



Einführung

ISG

Facetten

Discus

Take Home

Facettensyndrom

The lumbar facet joint: a review of current knowledge: part 1: anatomy, biomechanics, and grading.

[Varlotta GP](#), [Lefkowitz TR](#), [Schweitzer M](#), [Errico TJ](#), [Spivak J](#), [Bendo JA](#), [Rybak L](#). Skeletal Radiol. 2010 Jul 13. [Epub ahead of print]

The lumbar facet joint: a review of current knowledge: Part II: diagnosis and management.

[Varlotta GP](#), [Lefkowitz TR](#), [Schweitzer M](#), [Errico TJ](#), [Spivak J](#), [Bendo JA](#), [Rybak L](#). Skeletal Radiol. 2010 Jun 26. [Epub ahead of print]

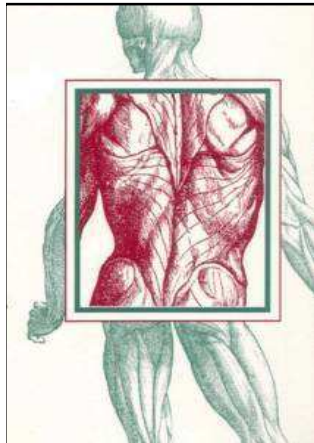
Pain Originating from the Lumbar Facet Joints.

[van Kleef M](#), [Vanelderen P](#), [Cohen SP](#), [Lataster A](#), [Van Zundert J](#), [Mekhail N](#). Pain Pract. 2010 Jul 26


Multicenter, randomized, comparative cost-effectiveness study comparing 0, 1, and 2 diagnostic medial branch (facet joint nerve) block treatment paradigms before lumbar facet radiofrequency denervation.

[Cohen SP](#), [Williams KA](#), [Kurihara C](#), [Nguyen C](#), [Shields C](#), [Kim P](#), [Griffith SR](#), [Larkin TM](#), [Crooks M](#), [Williams N](#), [Morlando B](#), [Strassels SA](#). Anesthesiology. 2010 Aug;113(2):395-405.

Kreuzschmerzen



Radiofrequenztherapie (RF) der Facettengelenke

Orthopädie OSS 1130 Wien, Speisingerstr. 109	Interventionsprotokoll Orthop. Schmerztherapie (Patient)	 ORTHOPÄDISCHES SPITAL WIEN SPIESING	Patientenetikette dient zur elektronischen Archivierung
R-pCC: 1.4.2 R-ISO: - sion: 01 ORT28	Qualitätsmanagement pCC inkl. KTQ		

Vom Patient auszufüllen:

Datum: _____ Intervention: _____

NRS	Vor Therapie	nach 0 Minuten	nach 1 Stunde	nach 2 Stunden	nach 3 Stunden	nach 4 Stunden	nach 5 Stunden	nach 6 Stunden	nach 12 Stunden	nach 24 Stunden
An diesem Ende der Skala haben Sie in der behandelten Region den maximal vorstellbaren Schmerz (100% Schmerz).										
100	<input type="checkbox"/>	<input type="checkbox"/>	<input type="checkbox"/>	<input type="checkbox"/>	<input type="checkbox"/>	<input type="checkbox"/>	<input type="checkbox"/>	<input type="checkbox"/>	<input type="checkbox"/>	<input type="checkbox"/>
90	<input type="checkbox"/>	<input type="checkbox"/>	<input type="checkbox"/>	<input type="checkbox"/>	<input type="checkbox"/>	<input type="checkbox"/>	<input type="checkbox"/>	<input type="checkbox"/>	<input type="checkbox"/>	<input type="checkbox"/>
80	<input type="checkbox"/>	<input type="checkbox"/>	<input type="checkbox"/>	<input type="checkbox"/>	<input type="checkbox"/>	<input type="checkbox"/>	<input type="checkbox"/>	<input type="checkbox"/>	<input type="checkbox"/>	<input type="checkbox"/>
70	<input type="checkbox"/>	<input type="checkbox"/>	<input type="checkbox"/>	<input type="checkbox"/>	<input type="checkbox"/>	<input type="checkbox"/>	<input type="checkbox"/>	<input type="checkbox"/>	<input type="checkbox"/>	<input type="checkbox"/>
60	<input type="checkbox"/>	<input type="checkbox"/>	<input type="checkbox"/>	<input type="checkbox"/>	<input type="checkbox"/>	<input type="checkbox"/>	<input type="checkbox"/>	<input type="checkbox"/>	<input type="checkbox"/>	<input type="checkbox"/>
50	<input type="checkbox"/>	<input type="checkbox"/>	<input type="checkbox"/>	<input type="checkbox"/>	<input type="checkbox"/>	<input type="checkbox"/>	<input type="checkbox"/>	<input type="checkbox"/>	<input type="checkbox"/>	<input type="checkbox"/>
40	<input type="checkbox"/>	<input type="checkbox"/>	<input type="checkbox"/>	<input type="checkbox"/>	<input type="checkbox"/>	<input type="checkbox"/>	<input type="checkbox"/>	<input type="checkbox"/>	<input type="checkbox"/>	<input type="checkbox"/>
30	<input type="checkbox"/>	<input type="checkbox"/>	<input type="checkbox"/>	<input type="checkbox"/>	<input type="checkbox"/>	<input type="checkbox"/>	<input type="checkbox"/>	<input type="checkbox"/>	<input type="checkbox"/>	<input type="checkbox"/>
20	<input type="checkbox"/>	<input type="checkbox"/>	<input type="checkbox"/>	<input type="checkbox"/>	<input type="checkbox"/>	<input type="checkbox"/>	<input type="checkbox"/>	<input type="checkbox"/>	<input type="checkbox"/>	<input type="checkbox"/>
10	<input type="checkbox"/>	<input type="checkbox"/>	<input type="checkbox"/>	<input type="checkbox"/>	<input type="checkbox"/>	<input type="checkbox"/>	<input type="checkbox"/>	<input type="checkbox"/>	<input type="checkbox"/>	<input type="checkbox"/>
0	<input type="checkbox"/>	<input type="checkbox"/>	<input type="checkbox"/>	<input type="checkbox"/>	<input type="checkbox"/>	<input type="checkbox"/>	<input type="checkbox"/>	<input type="checkbox"/>	<input type="checkbox"/>	<input type="checkbox"/>
An diesem Ende der Skala sind Sie in der behandelten Region absolut schmerzfrei (0% Schmerz).										

Wichtig: Ihre Schmerzen sind meist durch bestimmte Haltungen und Tätigkeiten zu provozieren, d.h. sie verschlechtern sich z.B. beim Gehen, Sitzen, Stehen, etc...
 Bitte beurteilen Sie die Intensität Ihrer Schmerzen vor und nach der Intervention bei genau diesen Haltungen bzw. Tätigkeiten.

Einführung

ISG

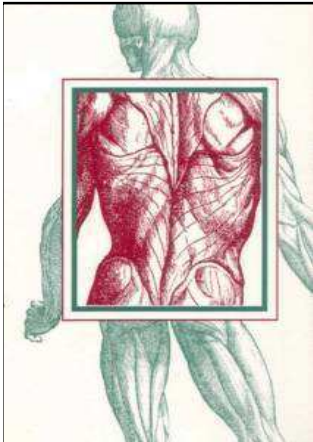
Facetten

Discus

Take Home

Bei einer **Schmerzreduktion von > 50 %** besteht die Indikation zur RF Therapie

Kreuzschmerzen



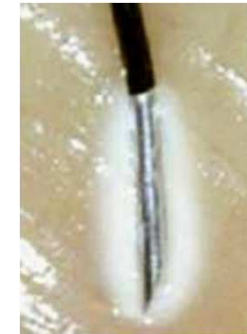Radiofrequenztherapie (RF) der Facettengelenke

= eine durch Hitze verursachte (reversible)
Nervenläsion der Rr. mediales

RF ist eine kontinuierlich angewandte Hochfrequenztechnik
(Frequenz 300 kHz bis 2 MHz):

- starkes elektrisches und schwaches magnetisches Feld
- dadurch induzierte Temperaturerhöhung

- **80 Grad Celcius**
- **90 Sekunden pro Läsion**



Einführung


ISG

Facetten

Discus

Take Home

Kreuzschmerzen



Einführung

ISG

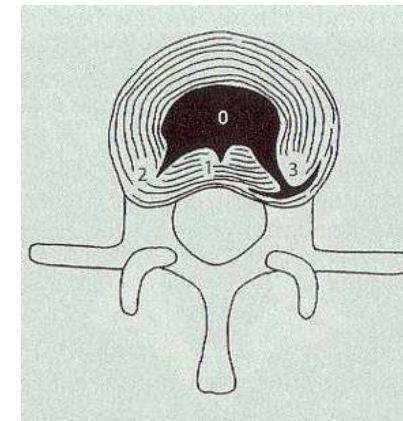
Facetten

Discus

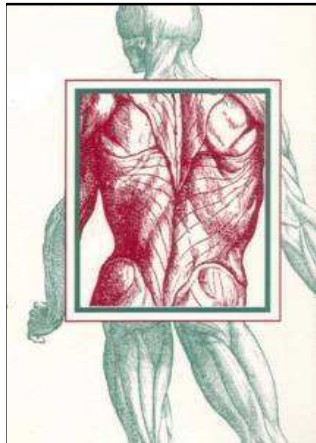
Take Home

Discogener Schmerz

- **Diszitis**
- **Torsionsverletzung**
- **Innere Diskusruptur :**
 - 3 Grade
 - **positiv, wenn die angrenzenden Bandscheiben den Schmerz nicht reproduzieren (!)**



Kreuzschmerzen



Einführung

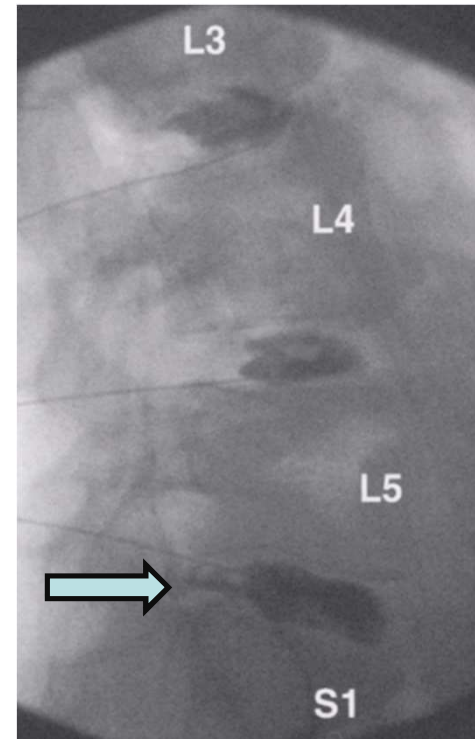
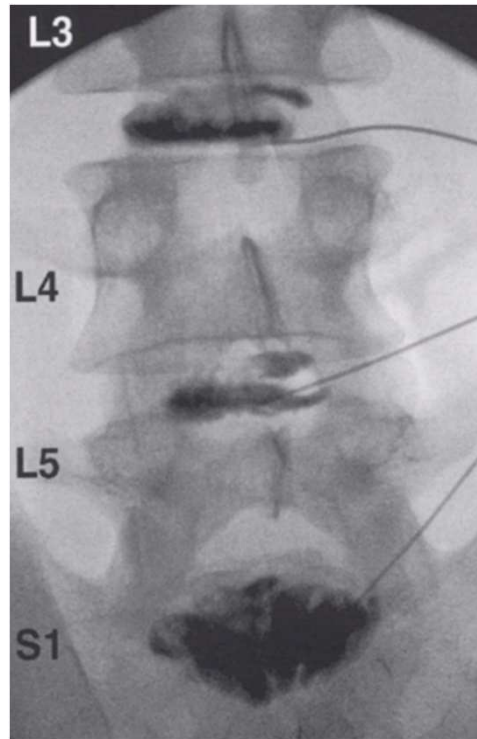
ISG

Facetten

Discus

Take Home

Discogener Schmerz

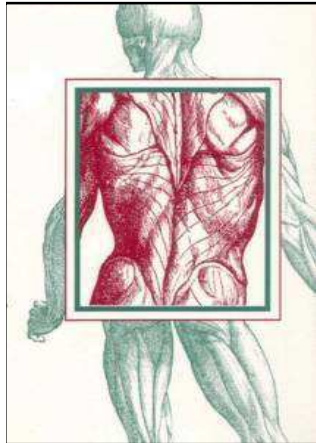


Provokationsdiscographie
mit periduralem KM-Austritt bei L5/S1

Kreuzschmerzen



Discogener Schmerz



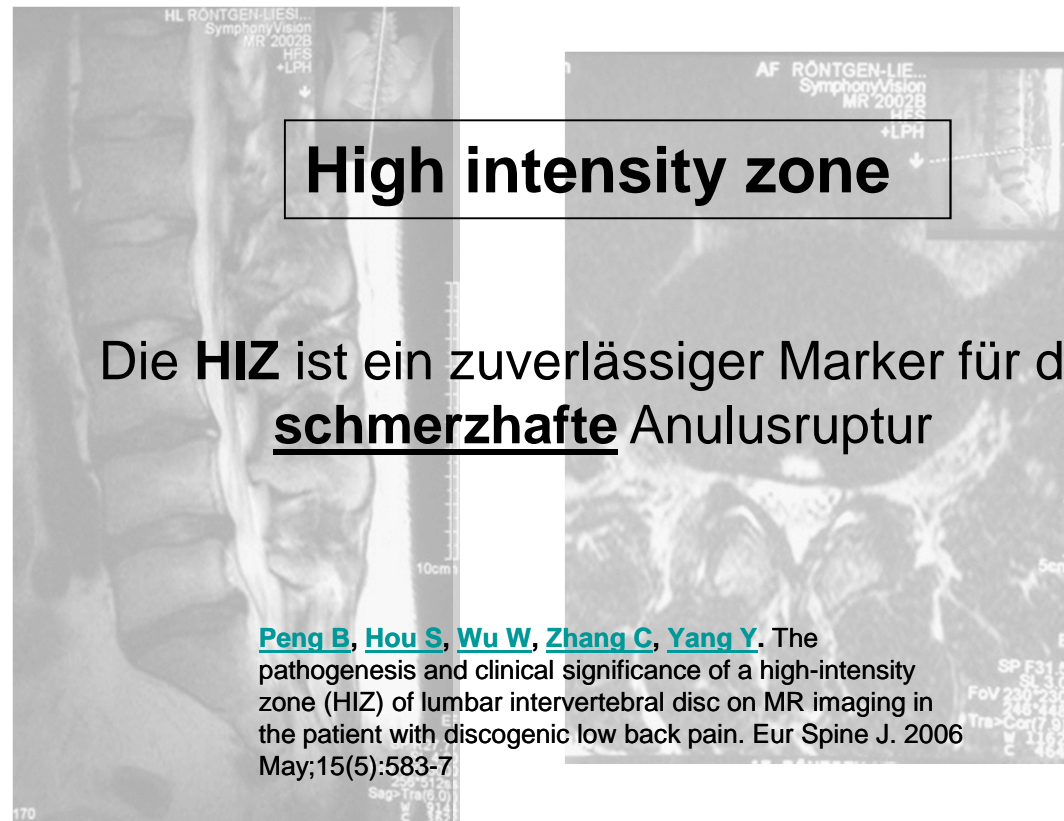
Einführung

ISG


Facetten

Discus

Take Home



Kreuzschmerzen



Discogener Schmerz

**„ständige tiefe Schmerzen, die durch die chemische Nozizeption auftreten und sich bei Bewegungen verstärken, die auf das betroffene Segment einwirken“
(Crock 1986)**

Einführung

ISG

Facetten

Discus

Take Home

[Spine J.](#) 2005 Jul-Aug;5(4):370-80.

Centralization as a predictor of provocation discography results in chronic low back pain, and the influence of disability and distress on diagnostic power.


[Laslett M](#), [Oberg B](#), [Aprill CN](#), [McDonald B](#).

[Spine \(Phila Pa 1976\)](#). 1997 May 15;22(10):1115-22.

A prospective study of centralization of lumbar and referred pain. A predictor of symptomatic discs and anular competence.

[Donelson R](#), [Aprill C](#), [Medcalf R](#), [Grant W](#).

Kreuzschmerzen



Discogener Schmerz

Biacuplastie

Bipolare, gekühlte Radiofrequenztherapie für Bandscheiben zur Koagulation und Druckentlastung des Diskus.

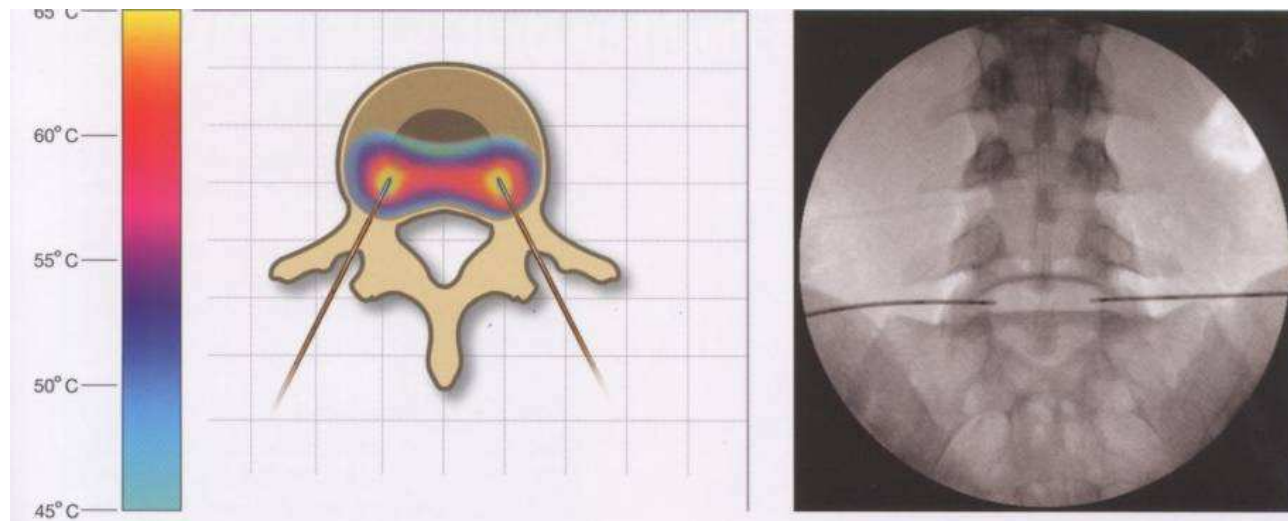
Einführung

ISG

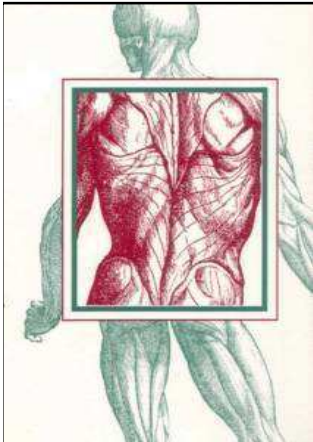
Facetten

Discus

Take Home



Kreuzschmerzen



Discogener Schmerz

Biacuplastie

Bipolare, gekühlte Radiofrequenztherapie für Bandscheiben zur Koagulation und Druckentlastung des Diskus.

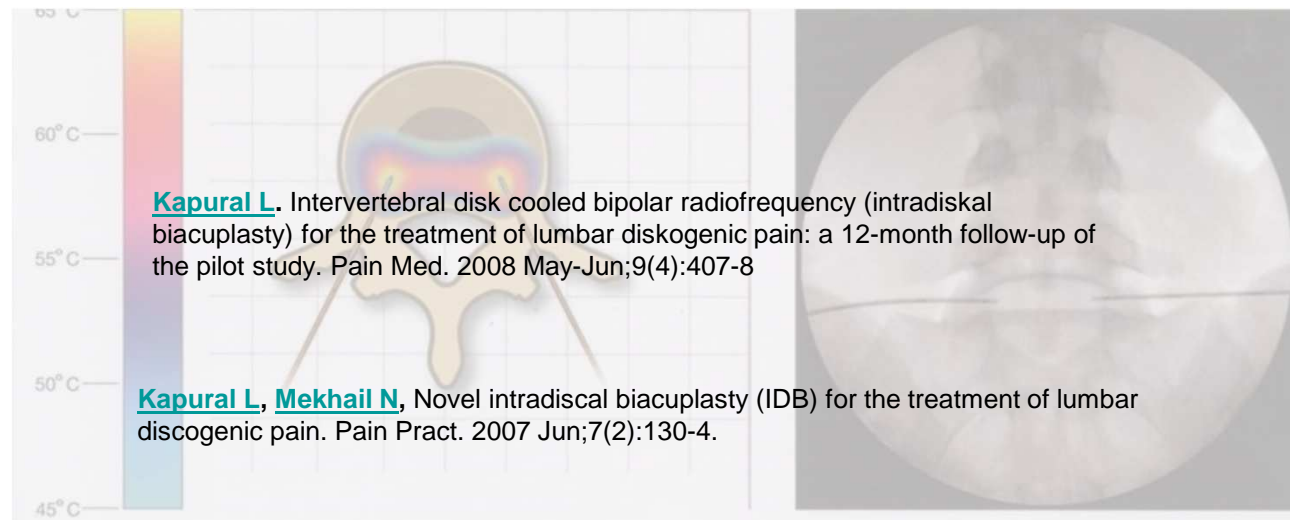
Einführung

ISG

Facetten

Discus

Take Home

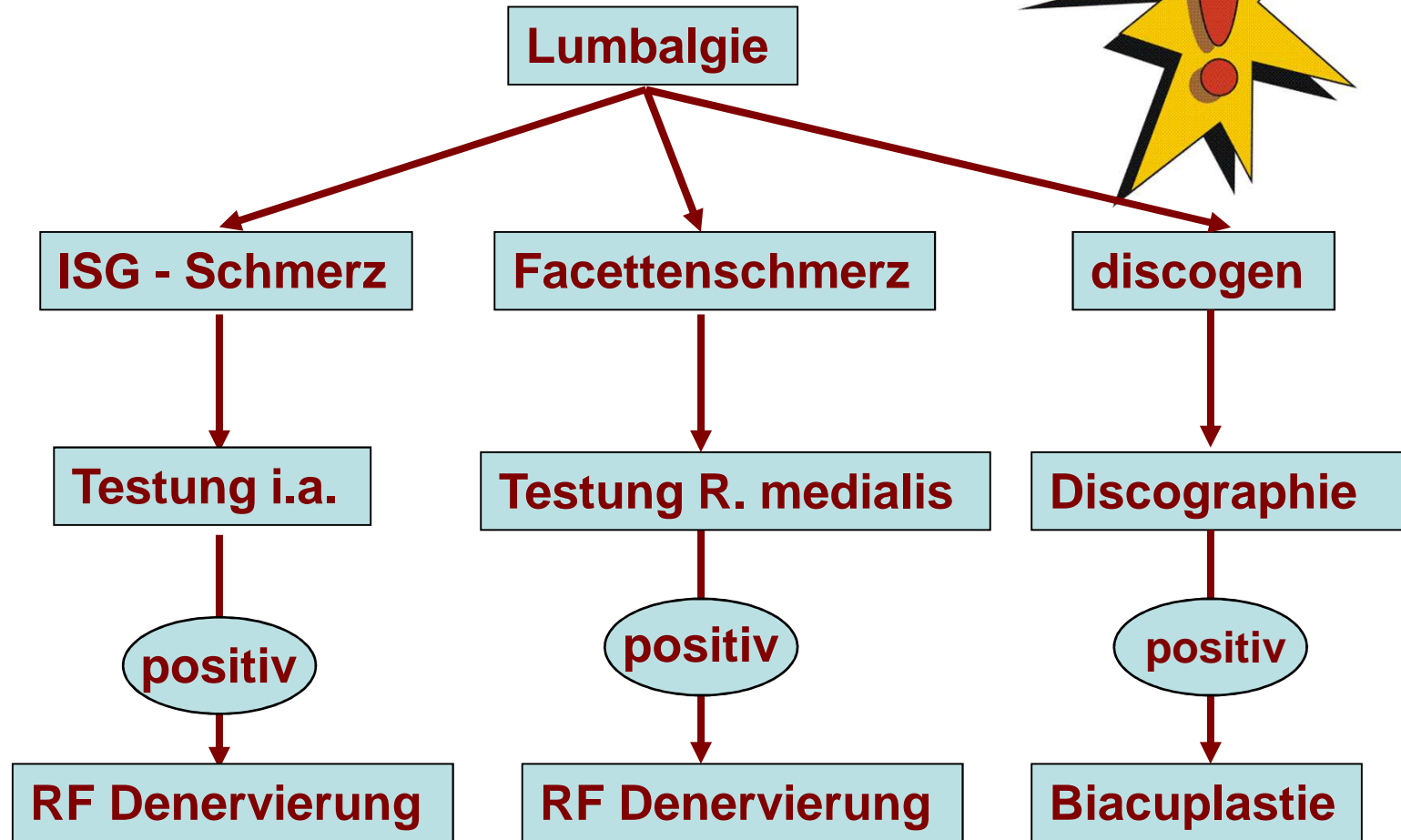


Kreuzschmerzen

Take Home Message

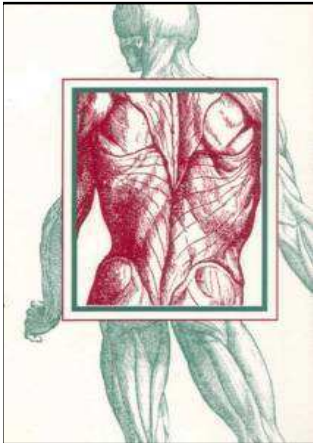


Einführung
ISG
Facetten
Discus
Take Home



Kreuzschmerzen

Take Home Message



Einführung

ISG

Facetten

Discus

Take Home

- 1. Facetten-, ISG- und discogener Schmerz sind „spezifisch“ !**
- 2. Ohne klinische Untersuchung keine Diagnose**
- 3. Ohne „Testung“ keine Intervention**